

# Fetal Echocardiography (2D and M-mode) in Pregnant Women with Insulin Dependent Diabetes in the Second Half of Pregnancy

---

*J. Wilczynski<sup>1</sup>, M. Respondek<sup>2</sup>, and T. Pertynski<sup>2</sup>*

<sup>1</sup> 2nd Department of Pregnancy Pathology

<sup>2</sup> Department of Sonography

Polish Mother's Memorial Hospital, Łódź, Poland

## **Abstract**

57 fetal echocardiographic examinations have been performed as part of a screening sonography evaluation in pregnant women with insulin dependent diabetes. We have analyzed fetal heart size, interventricular septum thickness, fetal heart rate, 4 chamber view and ventriculo arterial connections. There were no statistical differences as to heart size between the diabetic and the normal group:  $0.30 \pm 0.05$  and  $0.33 \pm 0.06$  respectively. There were statistical differences as to fetal heart rate between the diabetic and the normal group:  $147 \pm 10$  and  $137 \pm 6$  ( $p < 0.01$ ). The interventricular septal thickness was statistically higher than that of controls:  $4.3 \pm 0.9$  and  $3.5 \pm 0.7$  mm, respectively.

There was one case of ASD secundum and one Coarctation of aorta, one Duodenal Atresia and one Hydrocephalus without heart defects.

## **Zusammenfassung**

57 fötale echokardiographische Untersuchungen wurden als Teil einer Ultraschall-Screening-Untersuchung bei schwangeren Frauen

---

Correspondence to: Maria Respondek, MD, PhD, Department of Ultrasonography, Polish Mother's Memorial Hospital, Rzgowska 281/289, 93-345 Łódź, Poland, Fax +48 (42) 422653

Paper presented at the 10th World Congress of the International Society of Prenatal and Perinatal Psychology and Medicine (ISPPM) "The Unborn Child Within the Family", Cracow, Poland, May 15–17, 1992.

mit insulinabhängigem Diabetes durchgeführt. Wir haben die fötale Herzgröße, die Dicke des intraventrikulären Septums, die fötale Herzfrequenz, die Anordnung der vier Kammern und die ventrikuloarteriellen Verbindungen analysiert. Es fanden sich keine statistischen Differenzen zwischen der Herzgröße bei der diabetischen Gruppe im Vergleich mit der normalen:  $0.30 \pm 0.05$  und  $0.33 \pm 0.06$ . Jedoch fand sich eine statistische Differenz zwischen der Herzfrequenz bei der diabetischen Gruppe im Vergleich zu den Normdaten:  $147 \pm 10$  und  $137 \pm 6$  ( $p < 0.01$ ). Die intraventrikuläre Dicke des Septums war statistisch größer als die bei Kontrolluntersuchungen:  $4.3 \pm 0.9$  und  $3.5 \pm 0.7$  mm.

Es gab einen Fall von sekundärem Vorhofseptumdefekt, einen Fall von Verwachsung der Aorta, einen Fall von Duodenalatresie und einen Fall von Hydrocephalus ohne Herzfehler.

## Introduction

It is well accepted that in neonates of mothers with insulin dependent diabetes one may expect a higher incidence of congenital abnormalities compared to the offspring of mothers with normal carbohydrate metabolism<sup>1</sup>. Cardiac malformations and cardiomyopathy belong to the most common defects in newborns of diabetic mothers<sup>2</sup>. In this paper results of fetal echocardiographic examinations, performed from June 1st 1990 to December 30th 91, are reported as part of a screening sonography evaluation in pregnant women with diabetes.

**Table 1.** Qualitative data for diabetic group and control

			Diabetes	Control	Statis. diff.
HA/CA	(57)	(100 %)	$0.30 \pm 0.05$	$0.33 \pm 0.06$	$p > 0.05$
FHR	(57)	(100 %)	$147 \pm 10$	$137 \pm 6$	$p < 0.01$
IVS	(36)	(65 %)	$4.3 \pm 0.9$	$3.5 \pm 0.7$	$p < 0.01$

HA/CA – heart area / chest area in the 4 chamber view

FHR – fetal heart rate per min

IVS – septal thickness in mm

## Materials and Methods

57 consecutive echocardiography examinations were performed in pregnant women with diabetes. Acuson 128 XP or Toshiba 270 A supplied with 5 or 3 MHz transducers were used. All studies were recorded on video tapes. The following parts were followed during the echocardiographic examination:

1. fetal heart rate (FHR) assessment on the basis of umbilical Doppler wave form (frequency and regularity),

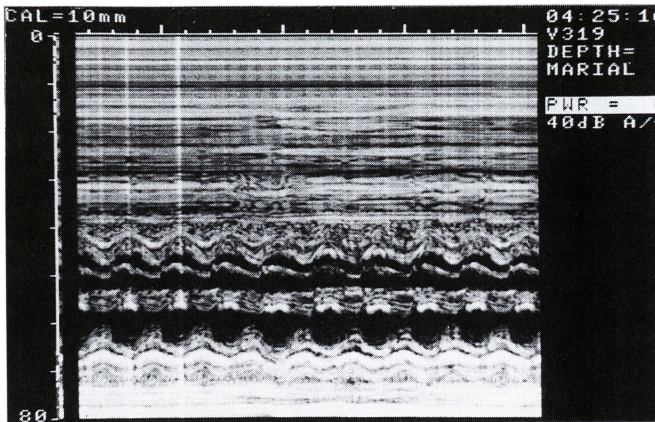


Fig. 1. M-mode tracing of interventricular septum in normal fetal heart

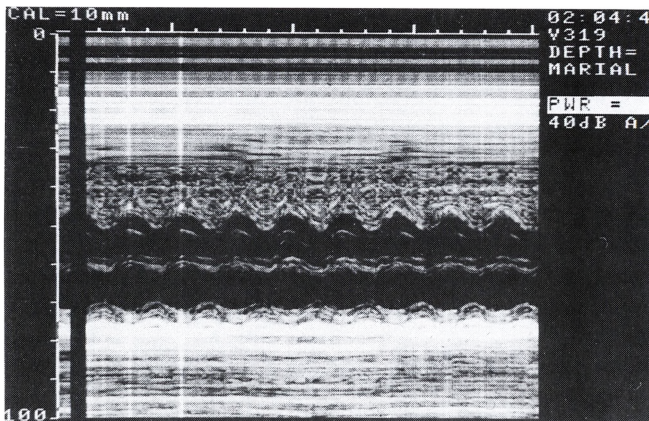
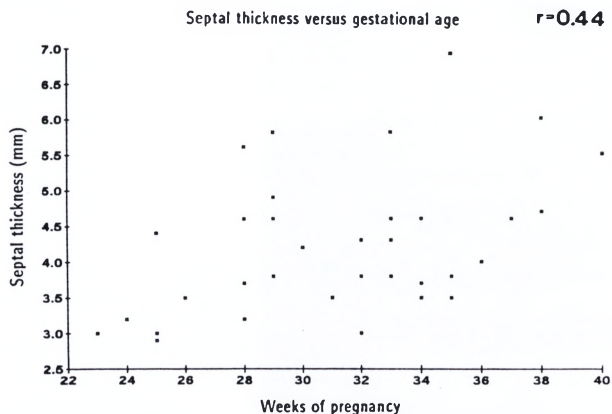


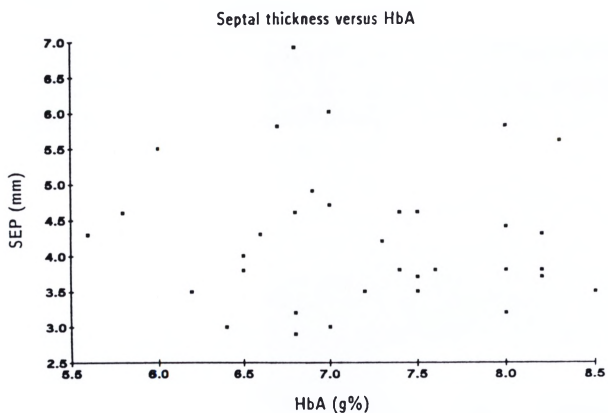
Fig. 2. M-mode tracing of interventricular septum in fetus heart of diabetic mother

2. fetal heart size (HA/CA) assessment on the basis of the ratio 4 chamber area divided by chest area<sup>3</sup>,
3. interventricular septum thickness measured from M-mode recording,
4. 4 chamber view, ventriculo-arterial connections, ductus and aortic arch evaluation from two-dimensional presentation.

This data was compared with 100 cases of fetal echocardiography performed in normal pregnancy with normal neonatal outcome. The average and standard deviations were calculated. The Student's test was used for statistical analysis, and coefficient correlations were calculated (linear regression) by using the Statgraf computer program.



**Fig. 3.** The diagram presenting interventricular septal thickness (SEP) according to gestational age in diabetic group of pregnancy



**Fig. 4.** The diagram presenting septal thickness (SEP) versus level of glycosylated hemoglobin (HbA)

## Results

We studied fetal hearts in class A-10, class B-11, class C-21, class F/R-8 and class R-7. There were no statistically significant differences as to HA/CA between diabetic and control group: ( $0.30 \pm 0.05$  and  $0.33 \pm 0.06$ , respectively). There were statistically significant differences as to fetal heart rate between diabetic and control group:  $147 \pm 10$  and  $137 \pm 6$  ( $p < 0.01$ ). The interventricular septal thickness measured from M-mode tracings was obtained in 36 out of 57 (65%) cases of the diabetic group and the average was statistically higher than that of controls: ( $4.3 \pm 0.9$  and  $3.5 \pm 0.7$  mm, respectively). Some typical examples of interventricular septum in M-mode tracings in normal and "diabetic" fetuses are presented in Figs. 1 and 2. There was a weak correlation ( $r = 0.44$ ) between septal thickness and gestational age (Fig. 3). There was no correlation between septal thickness



and the level of glycosylated hemoglobin (Fig. 4). Observing the heart morphology and ventriculo-arterial connections besides great arteries, we successfully recorded great arteries in 70%. There was one case of atrial septal defect (foramen ovale was 8 mm) and one coarctation of aorta, both confirmed by follow-ups of newborns. In this group, there was also one case of duodenal atresia and another case of hydrocephalus, both without heart defects. There were neither false positive nor false negative results as given evidence by neonatal follow-ups.

## Discussion

There is limited data on the fetal heart evaluation in diabetic pregnancy<sup>4,5</sup>. The most important aim of fetal echocardiography is to rule out congenital heart defects. Fetal heart size assessment may be useful for the screening of heart abnormalities, except for the transposition of great arteries, which may not change the 4 chamber view and the heart size. In our material there were only minor malformations affecting neither fetal intrauterine life nor neonatal outcome.

The most frequent abnormality in this series of patients was increased interventricular septal thickness of fetal heart. This problem has been already reported as a benign abnormality<sup>5</sup>, usually of no haemodynamic effect, which should resolve up to 6 months of age<sup>2,6</sup>. This abnormality was probably linked with fetal hyperinsulinemia, but it depends not only on metabolic control<sup>7</sup>. Our data confirms such hypotheses as we did not find any relation between septal thickness and the level of glycosylated hemoglobin. There is no data on the monitoring of fetal heart rate (FHR), which is relatively simple, especially from Doppler umbilical artery tracing, but also from M-mode tracings. In our material, fetuses of diabetic mothers showed mild tachycardia compared to the control group.

Conclusion: performing fetal echocardiographic examinations of diabetic pregnant women, one should be aware of the high possibility of congenital heart defect. When fetal heart anatomy is described as normal, one may expect normal fetal heart size, mild tachycardia and increased septal thickness.

*Acknowledgements.* We thank Andrzej Wojciechowski MD, PhD., Department of Sonography, Polish Mother's Health Center for his assistance in statistical analysis.

## References

1. Pijlman, B.M., Dekonig, W.B., Wladimiroff, J.W., and Steward, P.A. (1989). Detection of fetal structural malformations by ultrasound in insulin-dependent pregnant women. *Ultrasound Med Biol* **15**, 541–543
2. Mace, S., Hirschfeld, S.S., Riggs, T., Fanaroff, A., and Merkatz, I. (1979). Echocardiographic abnormalities in infants of diabetic mothers. *J Pediatrics* **95**, 1013–1019
3. Respondek, M., Respondek, A., Huhta, J.C., and Wilczynski, J. (1992). 2D echocardiographic assessment of the fetal heart size in the second and third trimester of uncomplicated pregnancy. *Europ J Obstet Gynecol* **44**, 185–188
4. Weber, H.S., Copel, J.A., Reece, A.E., Green, J., and Kleinman, C.S. (1991). Cardiac growth in fetuses of diabetic mothers with good metabolic control. *J Pediatr St. Louis* **118**, 103–107

5. Kleinman, C.S. (1988). Diabetes and the fetal heart: Application of fetal echocardiography. In: Reece, E.A. and Coustan, D.R. *Diabetes Mellitus in Pregnancy: Principles and Practice 15*. Churchill Livingstone, New York, pp. 363-373
6. Reller, M.D. and Kaplan, S. (1988). Hypertrophic cardiomyopathy in infants of diabetic mothers. *Am J Perinatol* 5, 353-358
7. Sheehan, P.Q., Rowland, T.W., Shah, B.L., McGravey, V.J., and Reiter, E.O. (1986). Maternal diabetic control and hypertrophic cardiomyopathy in infants of diabetic mothers. *Clin Pediatr Phila* 25, 266-271